

Emphysematous Gastritis in an 88-Year-Old Male: A Case Report

✉ Fatih Kıvrakoğlu¹, ✉ Cihan Atar², ✉ Denizhan Kılıç², ✉ Alişan Berk Deniz², ✉ Sevilay Kıvrakoğlu³, ✉ Mustafa Ergin⁴

¹Osmaniye State Hospital, Clinic of Gastroenterology, Osmaniye, Turkey

²Osmaniye State Hospital, Clinic of General Surgery, Osmaniye, Turkey

³Osmaniye State Hospital, Clinic of Intensive Care Unit, Osmaniye, Turkey

⁴Aksaray Training and Research Hospital, Clinic of Gastroenterology, Aksaray, Turkey

ABSTRACT

Emphysematous gastritis is an uncommon, yet severe infection of the stomach caused by gas-producing bacteria. Due to the condition's non-specific presentation and high mortality rate, early recognition is crucial for improving patient outcomes. This case describes an 88-year-old male with a history of diabetes mellitus and congestive heart failure, who presented with abdominal pain, nausea, and hematemesis. A computed tomography scan confirmed emphysematous gastritis, revealing air within the gastric wall. Given his advanced age and comorbidities, the patient underwent conservative treatment, including broad-spectrum antibiotics, intravenous fluids, and nutritional support. Although his initial condition stabilized, he later developed hospital-acquired pneumonia, which led to respiratory failure and ultimately death on day sixteen of hospitalization. Managing emphysematous gastritis presents a significant challenge. While surgical treatment is recommended in some cases, conservative approaches involving aggressive antibiotic therapy and supportive care may serve as viable alternatives for high-risk patients. Timely diagnosis and individualized treatment strategies play a crucial role in optimizing outcomes. This report underscores the importance of early diagnosis and close monitoring in emphysematous gastritis. Clinicians should consider this rare condition in critically ill patients with acute gastrointestinal symptoms. Conservative management may be beneficial in select cases, though further research is necessary to define optimal treatment protocols.

Keywords: Emphysematous gastritis, Gas-forming bacteria, Gastrointestinal infection, Conservative treatment

INTRODUCTION

Emphysematous gastritis is a rare but potentially fatal condition characterized by the presence of gas-forming bacteria within the gastric wall. It often arises due to local bacterial invasion or hematogenous spread from a distant site. Affected individuals typically present with critical illness, systemic toxicity, and multiple comorbid conditions, making early diagnosis and management challenging [1]. Despite its severe nature, no universally accepted treatment protocol exists. In certain cases, total gastrectomy may be necessary for sepsis control and patient stabilization, but due to the frailty of affected individuals, surgical intervention may not always be feasible. This report highlights the clinical course and management of a patient diagnosed with emphysematous gastritis.

CASE REPORT

An 88-year-old male presented to the emergency department with complaints of persistent abdominal pain, nausea, and hematemesis. His medical history included diabetes mellitus, asthma, and congestive heart failure. On admission, he was conscious and cooperative, with unstable vital signs including hypotension (95/52 mmHg), tachycardia (132 bpm), and increased respiratory rate (26 breaths per minute). Physical examination revealed abdominal tenderness without peritoneal signs.

Laboratory investigations showed mild anemia [hemoglobin: 13.5 g/dL (reference range for males: 14-18 g/dL)], elevated white blood cell count [12,380/μL (reference range: 4,500-11,000/μL)], and significantly raised C-reactive protein (CRP)



Address for Correspondence: Fatih Kıvrakoğlu MD, Osmaniye State Hospital, Clinic of Gastroenterology, Osmaniye, Turkey

E-mail: dr.fkivrakoglu@gmail.com **ORCID ID:** 0000-0002-5388-794X

Received: 11.03.2025 **Accepted:** 11.08.2025 **Epub:** 20.08.2025 **Publication Date:** 29.08.2025

Cite this article as: Kıvrakoğlu F, Atar C, Kılıç D, Deniz AB, Kıvrakoğlu S, et al. Emphysematous gastritis in an 88-year-old male: a case report. J Cau Med Sci. 2025;3(2):15-17



Copyright© 2025 The Author. Published by Galenos Publishing House on behalf of Azerbaijan Gastroenterology and Invasive Endoscopy Society. This is an open access article under the Creative Commons Attribution-Attribution-NonCommercial 4.0 (CC BY-NC 4.0) International License.

[223 mg/L (reference range: 0-5 mg/L)]. His kidney function was impaired, with creatinine at 1.91 mg/dL (0.7-1.3 mg/dL) and blood urea nitrogen at 52 mg/dL (6-24 mg/dL). Serum potassium was elevated at 6.1 mmol/L (3.5-5.5 mmol/L). The Acute Physiology and Chronic Health Evaluation 2 score, calculated after the patient's admission to the intensive care unit (ICU), was 23.

A computed tomography (CT) scan identified intramural gas in the gastric wall and air within the portal vein, confirming emphysematous gastritis (Figure 1). Based on the patient's history, it was noted that no prior biliary interventions were recorded.

Upon admission to the ICU, the surgical team assessed the case and determined that, due to his advanced age and comorbidities, surgical intervention posed a high mortality risk [American Society of Anesthesiologists (ASA) physical status 4E]. Instead, a conservative treatment plan was initiated, involving bowel rest, intravenous hydration with central venous pressure monitoring, broad-spectrum antibiotics (meropenem and vancomycin), and total parenteral nutrition.

Following initial hemodynamic instability on admission, the patient achieved and maintained hemodynamic stability during the early phase of treatment, with no deterioration observed on physical examination. However, by the third day, he developed melena, and his hemoglobin levels dropped, prompting an urgent endoscopic evaluation. During endoscopy, a necrotic lesion covering a significant portion of the lesser curvature and posterior gastric wall was noted, bordered by hyperemic tissue indicative of healing (Figure 2).

Throughout hospitalization, his inflammatory markers showed improvement and abdominal tenderness resolved.

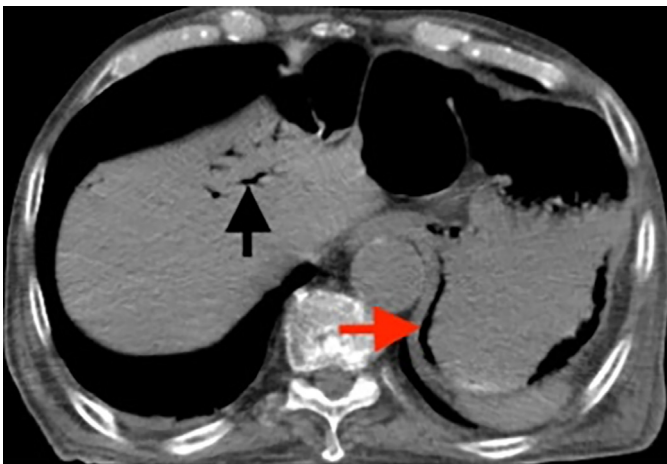

Figure 1. CT image of emphysematous gastritis and air in the portal venous

(The intramural gas is indicated by a red arrow, and the portal venous gas is indicated by a black arrow)

CT: Computed tomography

However, on the tenth day, a renewed elevation in CRP levels was observed (Figure 3). He developed respiratory distress, followed by a decline in oxygen saturation. Despite intensive respiratory support, he was diagnosed with hospital-acquired pneumonia, which worsened rapidly, necessitating intubation and mechanical ventilation on day eleven. Unfortunately, the patient succumbed to respiratory failure on the sixteenth day.

DISCUSSION

Emphysematous gastritis, first described by Dr. Frankel in 1889, is a rare but life-threatening gastrointestinal infection characterized by the presence of gas within the stomach wall due to gas-forming organisms such as *Clostridium*, *Escherichia coli*, *Streptococcus*, and *Pseudomonas species* [1-3]. Its incidence remains extremely low, with fewer than 100 cases reported in the literature to date [2]. Despite its rarity, the condition carries

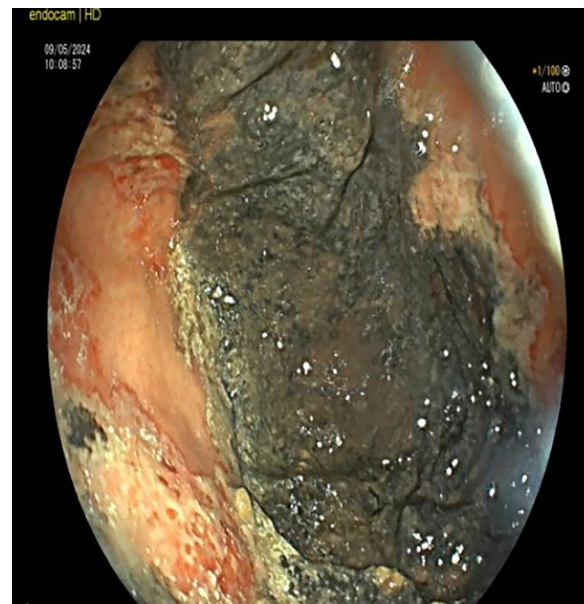


Figure 2. Endoscopic image of patient

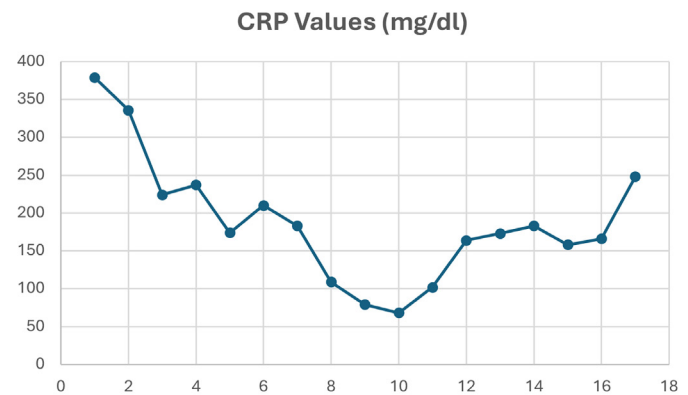


Figure 3. CRP values

CRP: C-reactive protein

a high mortality rate ranging from 55% to nearly 80%, especially in the absence of prompt and appropriate management [4,5]. High-risk populations include elderly individuals, patients with poorly controlled diabetes mellitus, immunosuppressed individuals, and those with chronic organ failure such as renal or cardiac dysfunction [1,4,6]. In our case, the patient was an 88-year-old male with diabetes mellitus, congestive heart failure, and acute kidney injury: multiple risk factors that likely contributed to the onset and poor prognosis.

A critical distinction must be made between emphysematous gastritis and gastric emphysema. While both conditions involve the presence of gas within the gastric wall, gastric emphysema is typically benign, often resulting from non-infectious causes such as instrumentation, vomiting, or trauma, and is not associated with systemic toxicity. Emphysematous gastritis, in contrast, is a fulminant infection with potential for rapid clinical deterioration and sepsis [1,5].

Diagnosis primarily relies on abdominal CT imaging, which typically reveals intramural gastric air and, in some cases, air within the portal venous system—both of which were present in our patient [1,7]. However, the absence of peritoneal signs or overt sepsis at presentation may delay diagnosis in some critically ill or elderly patients, emphasizing the need for clinical vigilance.

Management strategies are not standardized due to the rarity of the disease. In general, treatment includes bowel rest, aggressive intravenous fluid resuscitation, broad-spectrum antibiotics, and nutritional support. Surgical intervention, including total gastrectomy, may be necessary in cases with gastric necrosis, perforation, or clinical deterioration despite conservative measures [6]. In our case, surgery was deemed too high-risk due to the patient's frailty and ASA IV-E status, and a conservative approach was pursued.

When comparing our case to previously reported ones, favorable outcomes have been documented with conservative treatment, particularly in patients without overt perforation or hemodynamic collapse [4,7,8]. For instance, Singhanian et al. [4] described successful non-surgical management in a case with similar risk factors. However, other cases, such as the one reported by Liao et al. [6], necessitated early total gastrectomy to achieve survival, underscoring the importance of individualized decision-making. Unfortunately, despite initial stabilization in our patient, subsequent development of hospital-acquired pneumonia led to respiratory failure and death.

This case adds to the growing body of literature suggesting that conservative management can be effective in select high-

risk patients. Nonetheless, close monitoring for complications such as bleeding, necrosis, or secondary infections is essential. Further studies are required to determine clinical and imaging predictors of conservative treatment success and to establish evidence-based management protocols.

CONCLUSION

Emphysematous gastritis remains a life-threatening condition requiring prompt recognition and individualized treatment strategies. While surgical intervention may be lifesaving in some cases, conservative management can be an effective alternative in high-risk patients. This case emphasizes the importance of close monitoring and early identification of complications to improve patient outcomes. Given the lack of consensus on optimal management, further studies are warranted to establish clear guidelines for treating emphysematous gastritis.

Ethics

Informed Consent: A written informed consent has been granted from the patient.

Footnotes

Authorship Contributions

Concept: F.K., Design: A.B.D., Data Collection or Processing: C.A., A.B.D., Analysis or Interpretation: D.K., S.K., Literature Search: F.K., Writing: F.K., A.B.D.

Conflict of Interest: No conflict of interest was declared by the authors.

Financial Disclosure: The authors declared that this study received no financial support.

REFERENCES

1. Al-Jundi W, Shebl A. Emphysematous gastritis: case report and literature review. *Int J Surg*. 2008;6:e63-6.
2. Asharaf A, Desai P, Sanati M. Emphysematous gastritis. *J Am Osteopath Assoc*. 2019;119:848.
3. Moosvi A.R, Saravolatz L.D, Wong D.H, Simms S.M. Emphysematous gastritis: case report and review. *Reviews of Infectious Diseases*. 1990;12:848-55.
4. Singhanian N, Bansal S, Singhanian G, Singh A. Emphysematous gastritis. *J Emerg Med*. 2020;59:e259-61.
5. Lee SM, Kim GH, Kang DH, Kim TO, Song GA, Kim S. Education and imaging. gastrointestinal: emphysematous gastritis. *J Gastroenterol Hepatol*. 2007;22:2036.
6. Liao CS, Tu CW, Chiang CC, Shieh MC. Early total gastrectomy in emphysematous gastritis. *Advances in Digestive Medicine*. 2020;7:227-30.
7. Takase R, Fukuda N, Sui O, Hagiya H. Emphysematous gastritis. *Clin Case Rep*. 2021;9:e05094.
8. Ono R, Ito R, Yamamoto K, Aoki K, Kobayashi Y. Emphysematous gastritis. *BMJ Case Reports*. 2022;15:e251314.